

## 5 Seeing if the Fallopian tubes are obstructed (tubal patency)

Blocked tubes are a common cause of infertility. Hysterosalpingo-contrast-sonography (Hy-Co-Sy) is a modification of the sonohysterography procedure that involves injecting a special fluid that is easily identified on ultrasound into the uterus. The fluid can be seen as it passes along the Fallopian tubes and this will show if there is any blockage. The fluid (ultrasound contrast medium) used in this procedure is not covered by Medicare and the expense is to be met by the patient. It is important that the secretary is notified when the examination is for tubal patency so that Sydney Ultrasound for Women can ensure the special fluid is available.

### Will it be painful ?

Sonohysterography does not require hospitalisation, anaesthetic or analgesia. Around 2% of women describe period-like discomfort during or shortly after the procedure.

### When should it be done ?

If there is a chance of pregnancy, the procedure should be performed in the first 10 days of the menstrual cycle. This avoids the chance of the sonohysterography interfering with implantation of the embryo. This test should not be performed during pregnancy.

SYDNEY ULTRASOUND *for* WOMEN



# Sonohysterography

SYDNEY ULTRASOUND *for* WOMEN



#### Locations:

Suite 3  
29 Belmore Street  
**Burwood** 2134  
TEL 02 9745 4054  
FAX 02 9744 8854

1st Floor  
56 Neridah Street  
**Chatswood** 2067  
TEL 02 9413 9196  
FAX 02 9413 3863

1st Floor, Suite 7  
22 Belgrave Street  
**Kogarah** 2217  
TEL 02 9553 9611  
FAX 02 9587 4880

Suite 205, 2nd Floor  
161 Bigge Street  
**Liverpool** 2170  
TEL 02 9822 8447  
FAX 02 9822 7761

RPAH Medical Centre  
404/100 Carillon Ave  
**Newtown** 2042  
TEL 02 9516 2064  
FAX 02 9550 6257

Randwick Specialist  
Medical Centre  
135 Belmore Road  
**Randwick** 2031  
TEL 02 9399 9255  
FAX 02 9399 9153

2nd Floor  
4 O'Connell Street  
**Sydney** 2000  
TEL 02 9221 8099  
FAX 02 9235 3968

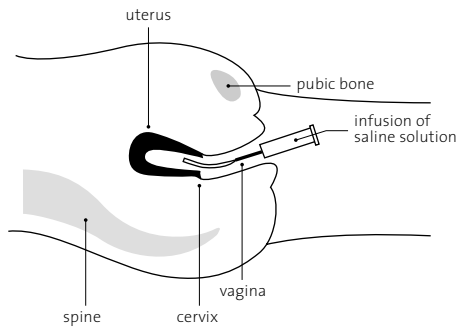
For more information visit our website at >

[www.sufw.com.au](http://www.sufw.com.au)



## What is sonohysterography ?

Sonohysterography is a new technique developed to better image the uterine cavity. Sterile saline is infused through a soft plastic catheter placed in the cervix. The saline distends the uterine cavity allowing a much better view of the uterine cavity by transvaginal ultrasound. This technique may be used to assess abnormalities of the uterus and endometrium (lining of the womb) and also show whether the Fallopian tubes are blocked.



## Why is it performed ?

This procedure is used when :

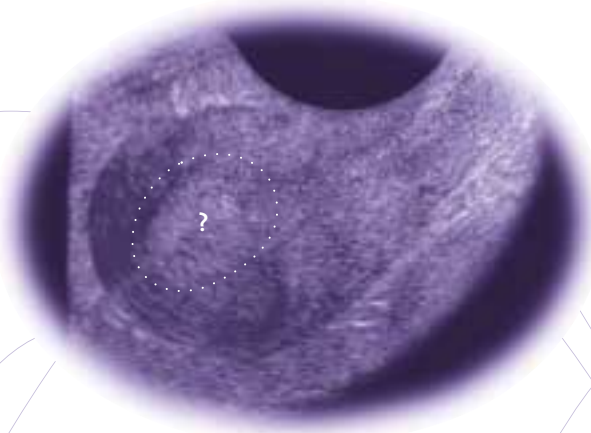
### 1 There is abnormal uterine bleeding (before or after menopause)

Many women have unusual bleeding around the time of menopause. This is often due to hormonal changes where surgery is of little benefit. If no obvious problems are seen within the uterus on sonohysterography there is no need for further investigation. Sometimes endometrial polyps will be found when the ultrasound appears normal.

### 2 A mass is suspected in the uterus on ultrasound

If a mass is found within the uterus, its type and size can be assessed prior to surgery. The most common findings are benign endometrial polyps, fibroids or a thickened uterine lining.

Suspected mass within the uterine cavity on transvaginal ultrasound >



### 3 Investigating infertility and recurrent miscarriage.

Sonohysterography can detect benign endometrial polyps or adhesions within the uterus which may prevent conception.

Recurrent miscarriage may be due to fibrous bands (septations) within the uterine cavity or to an abnormal uterine shape. These can be difficult to see using ultrasound alone but become clear on sonohysterography.

### 4 Assessing the uterine lining in patients on Tamoxifen therapy

A side effect of Tamoxifen therapy for breast cancer can be polyps, thickening, or even cancer, of the uterine lining. Sonohysterography can distinguish true abnormalities from thickening that happens beneath the uterine lining that is a common finding of no significance.

Endometrial polyp now clearly outlined after sonohysterography >

